

William C. Amalu, DC, DABCT, DIACT (B), FIACT

Board Certified Clinical Thermologist

Diplomate, International Academy of Clinical Thermology

Diplomate, American Board of Clinical Thermography

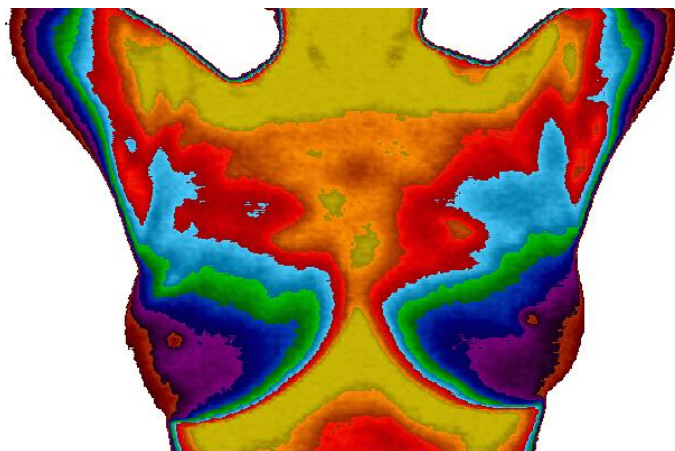
Diplomate, American Board of Medical Infrared Imaging

Member -

American Academy of Medical Infrared Imaging

International Academy of Clinical Thermology

International Thermographic Society



Normal TH1

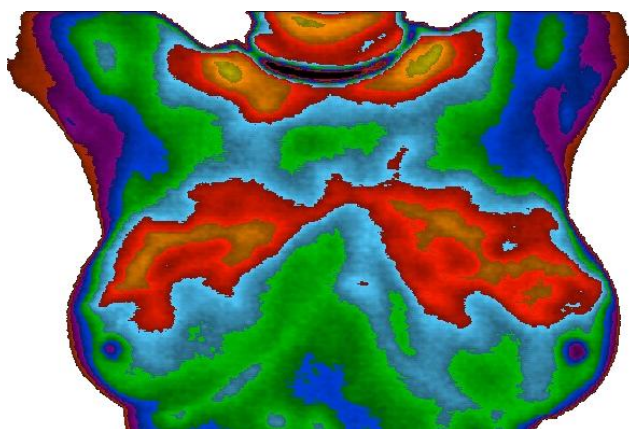

Cool inactive breasts

Breasts graded from TH1 - TH5

Abnormal TH4

Left breast highly active with blood vessels

Significant biological risk marker



Estrogen Dominance

Both breasts evenly active

Often seen with fibrocystic disease

Correlates with tenderness

Treatable for breast cancer prevention

Cooler Areas

Warmer Areas

